

6-1987

Radionuclide Imaging in Medullary Thyroid Carcinoma: Evaluation of Two New Radiopharmaceuticals

S. E. M. Clarke

C. R. Lazarus

M. N. Maisey

Follow this and additional works at: <https://scholarlycommons.henryford.com/hfhmedjournal>



Part of the [Life Sciences Commons](#), [Medical Specialties Commons](#), and the [Public Health Commons](#)

Recommended Citation

Clarke, S. E. M.; Lazarus, C. R.; and Maisey, M. N. (1987) "Radionuclide Imaging in Medullary Thyroid Carcinoma: Evaluation of Two New Radiopharmaceuticals," *Henry Ford Hospital Medical Journal* : Vol. 35 : No. 2 , 124-126.

Available at: <https://scholarlycommons.henryford.com/hfhmedjournal/vol35/iss2/13>

This Article is brought to you for free and open access by Henry Ford Health System Scholarly Commons. It has been accepted for inclusion in Henry Ford Hospital Medical Journal by an authorized editor of Henry Ford Health System Scholarly Commons.

Radionuclide Imaging in Medullary Thyroid Carcinoma: Evaluation of Two New Radiopharmaceuticals

S.E.M. Clarke,* C.R. Lazarus, and M.N. Maisey

We assessed the uptake of two new radiopharmaceuticals, ^{131}I meta-iodo-benzylguanidine (MIBG) and $^{99\text{m}}\text{Tc(V)}$ dimercaptosuccinic acid (DMSA), in patients with histologically proven medullary thyroid carcinoma (MTC). ^{131}I MIBG detected tumor in 40% of patients with known primary or recurrent tumor. $^{99\text{m}}\text{Tc(V)}$ DMSA successfully demonstrated primary and recurrent tumor in 86% of patients imaged, with true negative results in 100% of patients imaged after successful surgical resection and a false-negative rate of 14%. We therefore suggest that $^{99\text{m}}\text{Tc(V)}$ DMSA is the imaging agent of choice in patients with both primary and recurrent disease. ^{131}I MIBG, with its high false-negative rate, has no place in tumor localization, but its potential role in therapy warrants further evaluation. (Henry Ford Hosp Med J 1987;35:124-6)

Although current research adds much to the genetic and biochemical knowledge of medullary thyroid carcinoma (MTC), the management of the patient with MTC remains a subject of debate, with present therapy limited to surgery for the initial tumor and local recurrence, and palliative external beam radiotherapy for distant metastases, although several chemotherapy trials are currently in progress. Recurrent disease is diagnosed biochemically by elevation of plasma calcitonin levels. Various imaging methods have been used to localize recurrent tumor, including ultrasound and computed tomography, and within the last few years exciting reports have appeared in the literature of tumor uptake by two new radiopharmaceuticals, ^{131}I meta-iodo-benzylguanidine (MIBG) and pentavalent $^{99\text{m}}\text{Tc}$ dimercaptosuccinic acid [$^{99\text{m}}\text{Tc(V)}$ DMSA]. ^{131}I MIBG was developed by Wieland et al (1) as a radiopharmaceutical for imaging pheochromocytomas. It is a guanethidine analogue and has been shown by Sisson et al (2) to localize accurately 90% of pheochromocytomas imaged. Since these tumors are neuroectodermally derived, it was logical to assess the uptake of MIBG in other similarly derived tumors. In 1984, the first report appeared from Endo et al (3) showing uptake of ^{131}I MIBG in the thyroid of a patient with hereditary MTC. In the same year, a further case report by Connell et al (4) appeared, again reporting thyroidal uptake of ^{131}I MIBG in a patient with bilateral pheochromocytomas and MTC. Since then, several other case reports demonstrating uptake have been published, and the sensitivity of uptake has been assessed in two reported series (5,6).

The second radiopharmaceutical which has recently appeared promising is $^{99\text{m}}\text{Tc(V)}$ DMSA. Unlike the trivalent preparation of DMSA used for renal studies, the pentavalent form has been shown by Ohta et al (7) to be taken up into a variety of tumors, including MTC. A further study (8) has shown that both primary and recurrent disease may be visualized and that good target-to-background ratios facilitate the accurate localization of disease

in both bone and soft tissue. In this study, we have evaluated ^{131}I MIBG and $^{99\text{m}}\text{Tc(V)}$ DMSA uptake in patients with MTC and have endeavored to assess their contribution to the management of patients with MTC.

Patients

Sixteen patients were included in the study: four with hereditary disease, and 12 with a sporadic form with no evidence of involved kindred on screening. The diagnosis of MTC was confirmed in all 16 patients by histological and immunocytochemical techniques. All patients also had $^{99\text{m}}\text{Tc}$ methylene diphosphonate (MDP) bone scans to assess the presence of bone metastases, and computed tomography and conventional radiography to assess extraosseous metastases, where appropriate.

Five patients were studied before initial surgery, and the remaining patients were studied either when elevated calcitonin levels suggested postoperative recurrence or to assess the success of surgical intervention. Ten patients, aged 25 to 86, were studied by both imaging techniques, and six other patients were studied with $^{99\text{m}}\text{Tc(V)}$ DMSA alone.

Methods

^{131}I MIBG

Before the study, all patients received blocking doses of Lugol's iodine to prevent uptake of free iodine by residual thyroid tissue. Patients were then imaged 24 and 48 hours after an

Submitted for publication: February 27, 1987.

Accepted for publication: April 29, 1987.

*Address correspondence to Dr. Clarke, Department of Nuclear Medicine, Guy's Hospital, London, SE1, England.

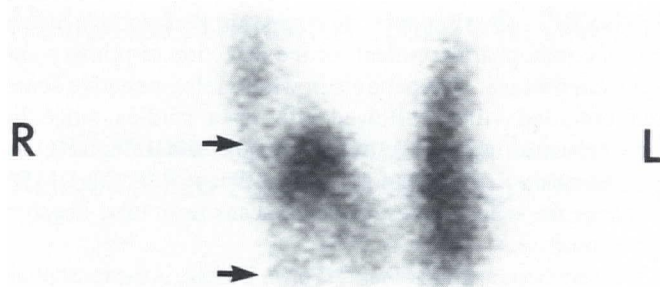


Fig 1— ^{99m}Tc pertechnetate scan of patient with primary medullary carcinoma involving the right lobe of the thyroid. Scan demonstrates two cold areas corresponding to sites of tumor (arrows).

intravenous injection of 1 mCi (37 MBq) ^{131}I MIBG. Whole body images were acquired using a standard, large field of view gamma camera and high-energy collimator interfaced to a data processor.

$^{99m}\text{Tc(V)}$ DMSA

Whole body images were obtained two hours after intravenous injection of 2 mCi (74 MBq) $^{99m}\text{Tc(V)}$ DMSA using a large field of view gamma camera and high-resolution collimator interfaced to a data processor.

Results

Primary diagnosis

One patient with bilateral palpable thyroid nodules was imaged with ^{131}I MIBG, and uptake was seen in both nodules. Surgery subsequently confirmed the histological diagnosis of bilateral MTC. Three patients with primary tumors were studied using $^{99m}\text{Tc(V)}$ DMSA, and uptake was seen in the thyroïdal region of two of these patients (Fig 1). The negative scan was obtained in a first-degree relative of a patient with proven MTC, who had a normal basal calcitonin level but an abnormal pentagastrin stimulation test.

Recurrent disease

^{131}I MIBG successfully detected recurrent tumor, both in bone and soft tissue, in three patients studied (Fig 2). Five patients, however, had negative ^{131}I MIBG scans despite known metastases. Another patient also had a negative ^{131}I MIBG scan. This patient was asymptomatic, had marginally elevated calcitonin levels, and had no tumor demonstrable by any other imaging technique. ^{131}I MIBG imaging therefore had a sensitivity of 40% in the group of patients studied with primary and recurrent disease.

$^{99m}\text{Tc(V)}$ DMSA successfully detected both local and distant metastases in ten patients studied (Figs 3 and 4). Negative scans were obtained in three patients, two of whom were imaged postoperatively after successful surgical clearance and in whom the postoperative calcitonin levels returned to normal. One patient, however, had a negative $^{99m}\text{Tc(V)}$ DMSA scan; this was the patient with an elevated postoperative calcitonin level, in whom

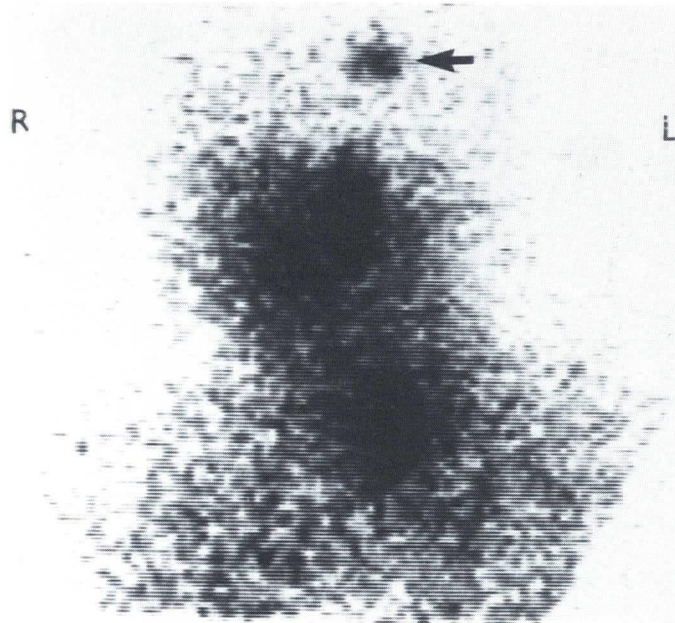


Fig 2— ^{131}I MIBG scan of skull at 24 hours demonstrating uptake in left parietal bone metastasis (arrow).

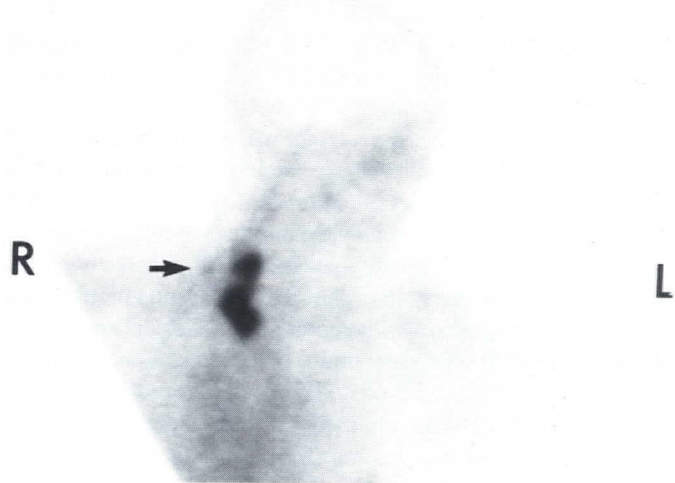

Fig 3— $^{99m}\text{Tc(V)}$ DMSA scan at two hours of anterior cervical region of patient in Fig 1 with uptake at sites of primary tumor in thyroid with uptake also seen in local lymph node (arrow).

all imaging techniques, including ^{131}I MIBG scanning, failed to identify recurrent tumor. $^{99m}\text{Tc(V)}$ DMSA was therefore demonstrated in this study to give a sensitivity in detection of tumor of 86%, with a specificity of 100%, and a false-negative rate of 14%.

Discussion

The detection of primary tumor in MTC has classically been undertaken using ^{99m}Tc pertechnetate to demonstrate the unilateral cold nodules in the thyroid or the bilateral nodules in

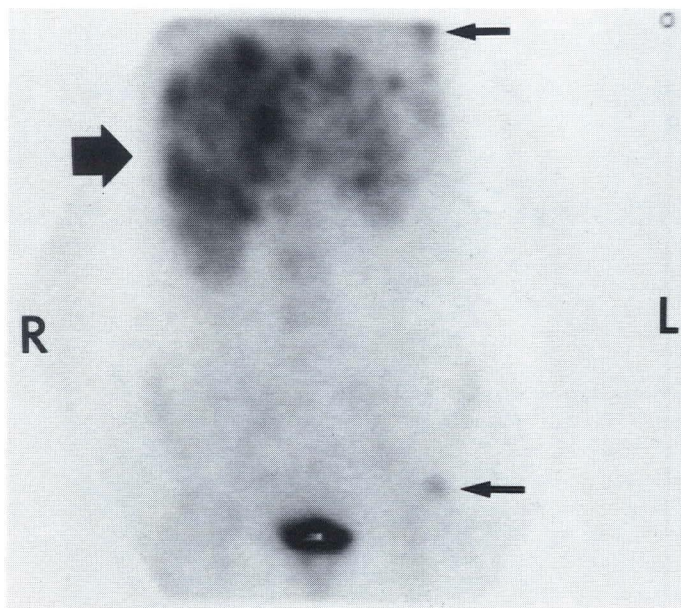


Fig 4— $^{99m}\text{Tc}(\text{V})$ DMSA scan at two hours of anterior abdomen and pelvis of patient with proven multiple hepatic, rib, and pelvic metastases (arrows) showing uptake in sites of known tumor.

patients with hereditary MTC (9). Ultrasound scanning has complemented this radionuclide technique by confirming the solid nature of these nodules.

The localization of recurrent tumor using radionuclide methods in postoperative patients whose calcitonin levels remain elevated, or subsequently become elevated, has relied on ^{99m}Tc MDP bone scanning to detect bone metastases and ^{99m}Tc sulphur colloid to demonstrate hepatic metastases (10). Uptake of ^{99m}Tc MDP has also been demonstrated in extrasosseous metastases (10,11), but many patients with known soft tissue deposits do not take up ^{99m}Tc MDP. Recurrent tumor in the neck has been investigated using both ultrasound and computed tomography, but these techniques are unable to distinguish accurately nodes that are involved with recurrent tumor from those that are enlarged due to inflammatory change. ^{67}Ga citrate has not been successful in demonstrating MTC (12), but ^{201}Tl thallous chloride has been used to image primary and recurrent thyroid carcinomas, including MTC (13-15).

^{131}I MIBG has been shown in this study, and in other studies (5,6), to have a low sensitivity in detecting MTC when compared with its successful use in demonstrating pheochromocytomas and neuroblastomas (2,16). Poor image quality and high radiation dose suggest that this radiopharmaceutical does not have a primary role in localization of tumors in patients with MTC. However, its β -emitting label gives it therapeutic potential, and further work is required to assess its place in therapy in patients whose tumors accumulate ^{131}I MIBG.

$^{99m}\text{Tc}(\text{V})$ DMSA has been shown in this study to be a highly sensitive radiopharmaceutical for the detection of primary and recurrent disease. The patients in whom false-negative scans were obtained will be followed with repeat studies, since the negative scans may be due to microscopic tumor deposits that will ultimately develop and take up sufficient $^{99m}\text{Tc}(\text{V})$ DMSA to change the status of these patients' scans from false-negative to true positive.

We have demonstrated that $^{99m}\text{Tc}(\text{V})$ DMSA is the radiopharmaceutical of choice for imaging patients with primary and recurrent MTC, since accurate localization of tumor recurrence facilitates surgical removal and also provides an objective means of assessing response to treatment.

Acknowledgment

This work was supported by a grant from the Cancer Research Campaign.

References

1. Wieland DM, Wu JU, Brown LE, Mangner TJ, Swanson DP, Beierwaltes WH. Radiolabelled adrenergic neuro-blocking agents: Adrenomedullary imaging with iodine 131 meta-iodobenzylguanidine. *J Nucl Med* 1980;21:349-53.
2. Sisson JC, Frager MS, Valk TW, et al. Scintigraphic localization of pheochromocytoma. *N Engl J Med* 1981;305:12-7.
3. Endo K, Shiomi K, Kasagi K, et al. Imaging of medullary thyroid cancer with ^{131}I -MIBG. *Lancet* 1984;2:233.
4. Connell JMC, Hilditch TE, Elliott A, et al. ^{131}I -MIBG and medullary carcinoma of the thyroid. *Lancet* 1984;2:273-4.
5. Poston GJ, Thomas AMK, Macdonald DWR, Lynn JA, Lavinder JP. ^{131}I -MIBG uptake by medullary carcinoma of the thyroid. *Lancet* 1985;2:560.
6. Hilditch TE, Connell JM, Elliott A, Murray T, Reed NS. Poor results with technetium- $^{99m}(\text{V})$ DMS and iodine- 131 MIBG in the imaging of medullary thyroid carcinoma. *J Nucl Med* 1986;27:1150-3.
7. Ohta H, Endo K, Fujita T, et al. Imaging of head and neck tumors with technetium (V)- 99m DMSA. A new tumor seeking agent. *Clin Nucl Med* 1985;10:855-60.
8. Ohta H, Yamamoto K, Endo K, et al. A new imaging agent for medullary carcinoma of the thyroid. *J Nucl Med* 1984;25:323-5.
9. Anderson RJ, Sizemore GW, Wahner HW, et al. Thyroid scintigraphy in familial medullary CA of the thyroid gland. *Clin Nucl Med* 1978;3:147-9.
10. Johnson DG, Coleman RE, McCook TA, Dale JA, Wells SA. Bone and liver images in medullary carcinoma of the thyroid gland: Concise communication. *J Nucl Med* 1984;25:419-22.
11. Hartsthorpe MF, Karl RD Jr, Cawthon MA, et al. Multiple imaging techniques demonstrate a medullary carcinoma of the thyroid. *Clin Nucl Med* 1983;8:628-9.
12. Parthasarathy KL, Shimaoka K, Bakshi S, et al. Radiotracer uptake in medullary carcinoma of the thyroid. *Clin Nucl Med* 1980;5:45-8.
13. Talpos GB, Jackson CE, Froelich JW, Kambouris AA, Block MA, Tashjian AH Jr. Localization of residual medullary thyroid cancer by thallium/technetium scintigraphy. *Surgery* 1985;98:1189-96.
14. Arnstein NB, Juni JE, Sisson JC, Lloyd RV, Thompson NW. Recurrent medullary carcinoma of the thyroid demonstrated by thallium-201 scintigraphy. *J Nucl Med* 1986;27:1564-8.
15. Hoefnagel CA, Delprat CC, Marcuse HR, Vijlder JJM. Role of thallium-201 total-body scintigraphy in follow-up of thyroid carcinoma. *J Nucl Med* 1986;27:1854-7.
16. Trennor J, Feine U, Neighammer D, et al. Scintigraphic imaging of neuroblastoma with ^{131}I metaiodobenzylguanidine (letter). *Lancet* 1984;1 (February 11):333-4.